

# SAFETY AND EFFICACY OF THE “RIALTO” TECHNIQUE: AN EXPLORATIVE TRIAL

S. Volpe<sup>1</sup>, M. Di Girolamo<sup>1,2</sup>, S. Zicari<sup>3</sup>, F. Cecchetti<sup>4</sup>, L. Volpe<sup>1</sup> and M. Turco<sup>1</sup>

<sup>1</sup>Private Practice, Rome, Italy;

<sup>2</sup>Department of Biomedicine and Prevention, University of Rome “Tor Vergata”, Rome, Italy;

<sup>3</sup>Department of SARAS, Sapienza University of Rome, Rome, Italy;

<sup>4</sup>Dept. of Social Dentistry and Gnathological Rehabilitation, National Institute for Health, Migration and Poverty (NIHMP), Roma, Italy

## Correspondence to:

Stefano Volpe, DDS

Private Practice,

Piazza del Fante 10,

00195, Rome, Italy

e-mail: [studiostefanovolpe@tiscali.it](mailto:studiostefanovolpe@tiscali.it)

## ABSTRACT

A series of patients were treated with the “Rialto” maxillary sinus lift technique. The primary aim of the present study is to evaluate the percentage of intraoperative complications such as perforation of the sinus mucosa and benign paroxysmal positional vertigo (BPPV). The second aim is to assess bone regeneration within the maxillary sinus with the sole use of collagen and clotting after 9-24 months of prosthetic loading. Twenty patients, 8 females and 12 males aged between 20 and 72 years participated in this study, treated consecutively from 2019 to 2021 with the “Rialto” surgical technique to obtain transcresal maxillary sinus lift and simultaneous implant positioning. Nine implants with Ø 4x 9 mm (Neoss straight, Neoss Ltd, Arrogate, UK) n. 6 BTK evo Ø 4x 10 mm and n. 5 BTK safe Ø 3.7 x 10 mm [Biotec srl Povolaro di Dueville (VI)] Italy The implants were allowed to heal for 4 months before the second surgery. Osseointegration was evident in all 20 patients. The median vertical bone height (VBH) values increased significantly between the first surgery (median 6 mm; 25th-75th percentile, 5 mm-6 mm) and the follow-up (median 9 mm; 25°-75th percentile, 8 mm-9 mm). No case of rupture of the sinus mucosa was detected. No patient complained of benign paroxysmal positional vertigo. The transveolar approach using the “Rialto” technique provides high predictability for elevating the maxillary sinus floor. The method, which has minimally invasive characteristics, reduces the most common complications, such as perforation of the sinus mucosa and BPPV.

**KEYWORDS:** *maxillary sinus, minimally invasive, dental implants, sinus floor augmentation, bone regeneration, osseointegration*

## INTRODUCTION

The combination of post-extraction crest resorption and maxillary sinus pneumatization often limits the available bone height for implant placement in the posterior maxilla, requiring a regenerative procedure known as maxillary sinus lift. The maxillary sinus lift procedure, with a lateral approach or a transcresal approach, is surgical techniques that allow for the restoration of adequate vertical bone volume and, in some cases, simultaneous implant placement. Both lateral (1) and transcresal approaches are widely used and have shown a high success rate (2). The selection criteria between these two techniques are based on residual bone height (RBH), calculated as the distance from the maxillary sinus floor to the

Received: 24 September 2024

Accepted: 26 October 2024

Copyright © by LAB srl 2024

This publication and/or article is for individual use only and may not be further reproduced without written permission from the copyright holder. Unauthorized reproduction may result in financial and other penalties. Disclosure: All authors report no conflicts of interest relevant to this article.

crestal bone. The Sinus Consensus Conference in Boston (1996) and subsequent classifications have suggested the transcresal approach with RBH of 6-7 mm and lateral window sinus lift in the presence of 5 mm or less of bone below the sinus floor (3). Today, with new minimally invasive techniques using a transcresal approach, it is possible to perform sinus lift and simultaneous implant placement in sites with a residual bone height of  $\leq 5$  mm while maintaining an excellent implant survival rate (4-5).

Tatum in 1986 and later Summers in 1994 were the first to propose the transcresal approach, which involved lifting the maxillary sinus membrane in the direction of the crest, using a kit of osteotomes with the possibility of inserting filling materials and the simultaneous placement of the implant (6-7). Although it is a valid alternative to the more invasive lateral window technique, the main disadvantage is the possibility of inadvertently causing small lacerations of membrane if the osteotomes penetrate the sinus without being able to highlight them since the maneuver is performed without visually monitoring the lifting of the membrane. Despite this limitation, membrane perforation is less frequent compared to the lateral window technique (8). In 1997, Engelke et al. performed the crestal technique under endoscopic control, observing that the membrane could be lifted to 5 mm without the risk of perforation (9). In a multicentric study, Rosen et al. placed 174 implants in 101 patients using the "osteotome technique". After a loading period of 6 to 66 months, they achieved a success rate of 96% when the remaining bone height was  $\geq 5$  mm, whereas the percentage decreased to 85.7% with a residual bone height  $\leq 4$  mm (10). A retrospective study of 430 patients undergoing crestal maxillary sinus lift in sites with RBH  $\leq 5$  mm obtained 12 early failures, with 7.2% perforations and 0.5% benign paroxysmal vertigo. An interesting finding in this study is that they received an incidence of 1.1% perforations in sinuses with a narrow palatal-vestibular distance  $\leq 12$  mm, while the incidence increased to 16.1% in wide sinuses (11).

An additional complication with osteotomes is benign paroxysmal positional vertigo (BPPV), with an incidence reported in the literature between 1.25% and 3.06%. It is an otoneurological disorder, and its pathogenesis has been attributed to the detachment of otoliths from the utricular macula and their displacement to the semicircular canals during the basal cortical fracture maneuver of the maxillary sinus using osteotomes (12). Currently, the need for simultaneous bone grafting after maxillary sinus floor elevation is still controversial.

The possibility of new bone formation with the only elevation of the maxillary sinus membrane has been observed in studies on humans and animals (13-14). Lundgren et al. described a new technique reporting 100% success in implant survival and bone regeneration after 9 months of function in 12 sinus lifts performed on 10 patients. The technique involves the creation of a lateral window, removing it, lifting the sinus mucosa, implant insertion, and subsequently repositioning the bone window itself. The authors have demonstrated that the elevation of the mucosa and the creation of an empty space in which blood clots form determine the formation of new bone tissue (15). The transcresal sinus lift procedure mediated by osteotome can be performed with or without using bone grafting material such as allograft, autologous bone, or heterologous bone material. No significant differences in implant survival and success rates have been observed when comparing the two methods (16).

Pjetursson et al. radiologically evaluated bone remodeling after inserting 252 implants using the crestal technique with and without filling materials. The authors conclude that, without using graft material, only a moderate increase in bone around the implant circumference can be observed; in contrast, a substantial bone increase was radiographically observed with the use of graft material (17). The main purpose of this study is to evaluate the percentage of intraoperative complications such as sinus membrane perforation and benign paroxysmal positional vertigo. The second purpose is to assess bone regeneration within the maxillary sinus using only collagen and clotting after 9-24 months of prosthetic loading using the Rialto Technique.

## MATERIALS AND METHODS

Twenty patients participated in this study consecutively treated from 2019 to 2021 with the "Rialto" surgical technique to obtain transcresal maxillary sinus lift and simultaneous implant placement. A total of 9 implants of 4x9 mm (Neoss straight, Neoss Ltd, Arrogate, UK), 6 BTK Evo of 4x10 mm, and 5 BTK Safe of 3.7x10 mm [Biotec srl Povolaro di Dueville (VI) Italy] were inserted. All sinus lifts were performed by an experienced operator. The study was approved by the local ethics committee (Ethics Committee Lazio, Rome Italy Prot.739/CE).

The inclusion criteria were:

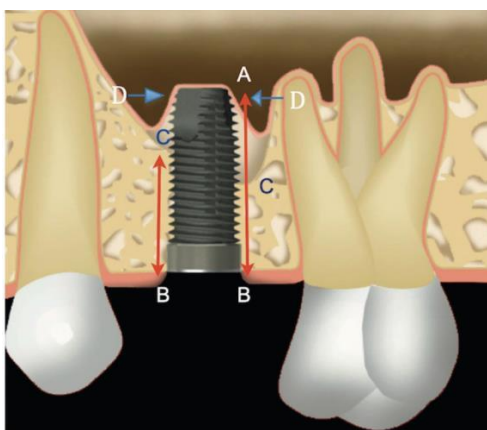
- I. premolar and molar edentulous area;
- II. presence of residual bone below the maxillary sinus of  $\geq 5$  mm where the implant was planned;
- III. the implant should not be inserted more than 5 mm into the maxillary sinus;
- IV. perfectly healed bone crest (at least 4 months must have passed since tooth extraction);
- V. age  $> 18$  years;

- VI. absence of endodontic lesions in neighboring teeth;
- VII. ability to understand the informed consent and signature of the same.

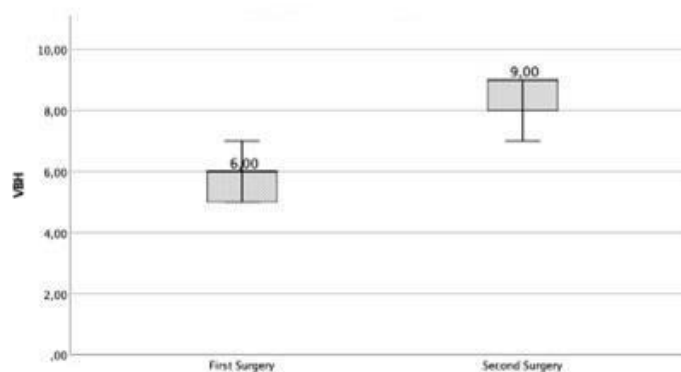
The exclusion criteria were:

- I. absolute contraindications to implant therapy (Hwang & Whang, 2006);
- II. irradiated head and/or neck;
- III. uncontrolled diabetes;
- IV. pregnancy;
- V. heavy smoker > 20 cigarettes per day;
- VI. poor oral hygiene;
- VII. acute and chronic maxillary sinus diseases;
- VIII. presence of sinus septa;
- IX. "severe" periodontal disease.

Preoperative evaluation includes the execution of a periapical endoral X-ray with the Rinn technique and, if necessary, a Cone Beam. Before each procedure, patients were informed about any risks and provided their consent to treatment. Each patient underwent postoperative follow-up visits to detect or intercept any complications induced by the surgical procedure. The implants were allowed to heal for 4 months before the second surgery. The follow-up includes the execution of endoral radiographs in three different phases for all patients: 1) before surgery to calculate the residual bone height (VBH); 2) immediately after implant placement; and 3) at a prosthetic loading follow-up from 13 to 43 months. For measurements, a magnifying lens (x4.5, Carl Zeiss, Oberkochen, Germany) and a caliber were used (Fig. 1, 2).



**Fig. 1.** A: implant apex; B: cresta position of the implant platform; C: sinus bone cortical level before surgery; D: most apical point of the sinus mucosa (immediately after surgery). B-C: bone crestal height before surgery (RBH); C-A: length of the implant inside the sinus; D: most apical point of new bone regeneration in contact with the implant at follow-up; D-C: bone gain within the sinus.

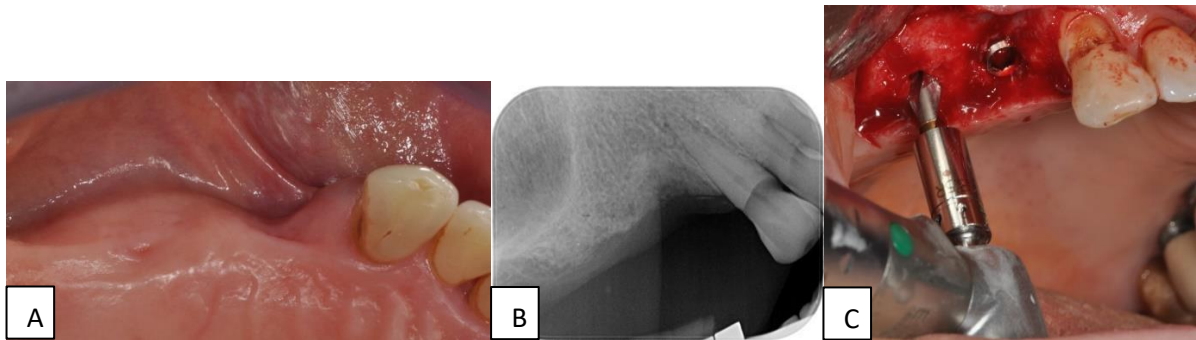


**Fig. 2.** VBH at first and second surgery.

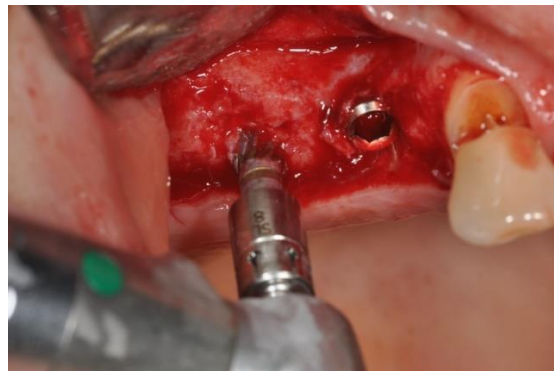#### Surgical and prosthetic procedure

Before the surgery, all patients were prescribed pharmacological therapy (Amoxicillin, Sandoz AS, Copenhagen, Denmark, 1gr. X 2 for 5 days) and anti-inflammatory medication (Ibuprofen, B. Braun Melsungen AG, Germany, 400 mg) 2 tablets X 2 times a day. Under local anesthesia (Mepivacaine 2%, Saint-Maur-des-Fosses, France), the implant site preparation was performed according to the standardized sequence of drills and manual instruments of the Rialto procedure as described below. The implant socket is prepared with a sequence of helical drills (HS) with increasing diameter ( $\varnothing$  2.0 - 2.60 - 3.0 mm) up to 1 mm from the cortical of the maxillary sinus. To work safely, HS drill stops are used. (Fig.3a-d). The preparation continues using "Multicutting" drills with  $\varnothing$  3.20, increasing the working depth (with

sinus lift drill stop) by 1 mm for each step until completely eroding the cortical below the mucosa. A rotational speed not exceeding 500 rpm is recommended. In addition to not damaging the sinus mucosa, the special feature of these drills is that they collect bone during drilling (Fig. 4).

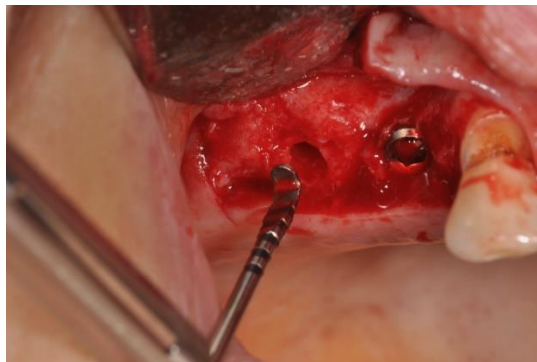


**Fig. 3.** *A): Occlusal view of the edentulous area, note the osteo mucosal vestibular depression at the level of 14; B): Initial Rx. Because of the edentulous area, the standardized placement with Rinn technique wasn't allowed. C): Use of HS helical drill sequence with depth stop.*

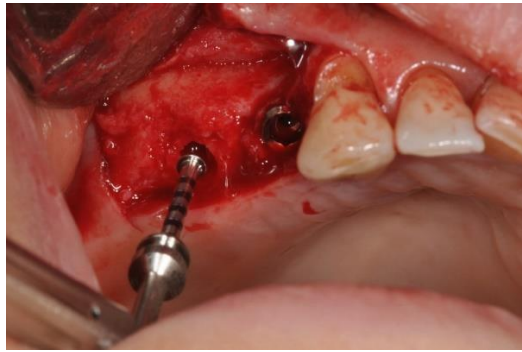


**Fig. 4.** *Use of a multi-cutter drill with a diameter of 3.2 mm.*

The manual tools "Sinus Lift" in the Rialto kit are used for the delicate next step, detachment and elevation of the sinus membrane. The internal and external 60° elevator has the function of detaching the membrane from the floor of the maxillary sinus (Fig. 5) while gently lifting the membrane continues with the rounded elevator of Ø 2.4 mm with a collagen sponge in between (Condress, Smith & Nephew, Agrate Brianza, Italy). This procedure can be repeated several times until the desired membrane elevation is achieved (Fig. 6).

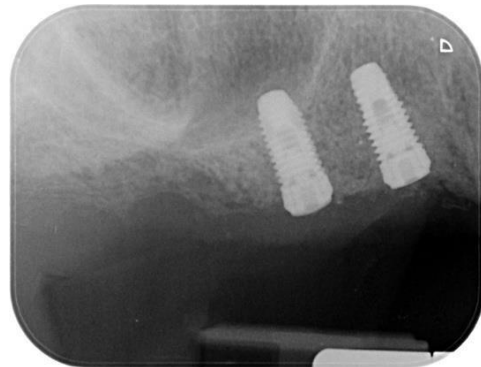
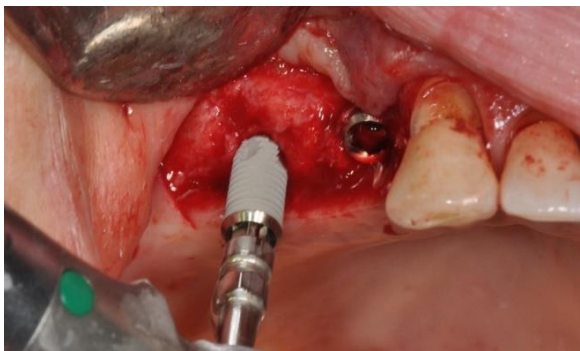


**Fig. 5.** *Initial detachment of the sinus mucosa with sinus lift (external and internal 60°) device.*



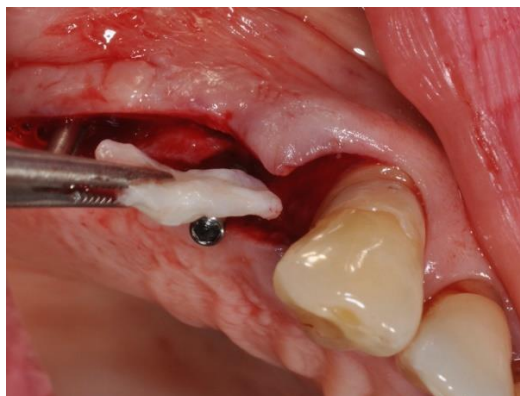
**Fig. 6.** Sinus elevation using 2.4mm rounded sinus lift with collagen membrane interposition.

In the presence of D1-D2 bone density, an additional drill from the system with a larger diameter than the last drill used for lower-density bone should be done before implant placement. A drill stop 1 mm below the sinus mucosa is recommended to rectify the socket preparation. The surgical procedure ends with implant placement, cover screw, and flap suturing with Supramid (B-Braun Surgical, S.A. Rubi Spain) 4.0 (Fig. 7a-b).



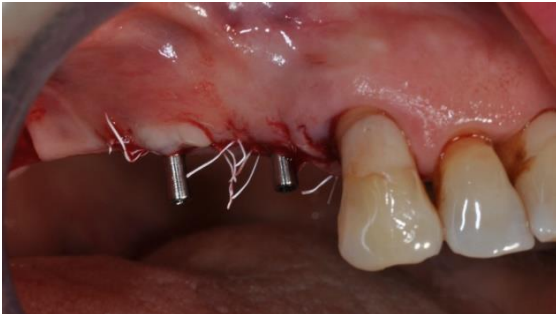**Fig. 7. A):** Implant placement; **B):** Immediate implant placement revealed a slight radiopacity at the apex of the implant caused by collagen-sponge.

The presence of any perforation of the sinus mucosa was evaluated with the Valsalva maneuver at each step of the procedure. All patients were advised to return after 10 days to remove the sutures and assess healing. Patients were followed up every 6-8 weeks, and any adverse events were recorded. After 4 months from the first surgical phase, the implants were uncovered, and a healing screw was inserted. In the case presented to correct the vestibular mucosal defect in zone 1.4, we performed a mucosal graft taken from the left tuberosity (Fig. 8).

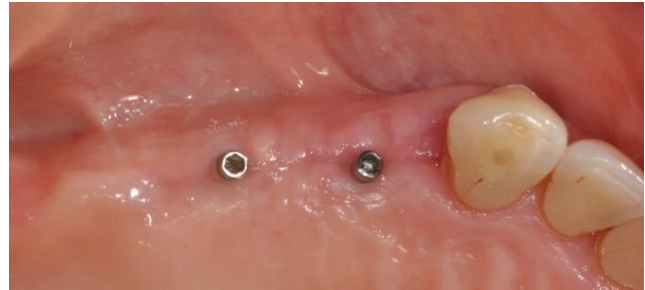

**Fig. 8.** Use of a connective tissue graft taken from the tuberosity to relieve the vestibular bone defect in zone 14.

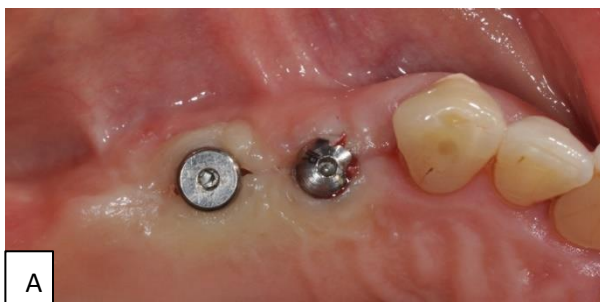We opted to insert two slim abutments (Fig. 9, 10) to facilitate wound healing. After about three weeks, they were replaced with standard healing screws (Fig. 11a, b).



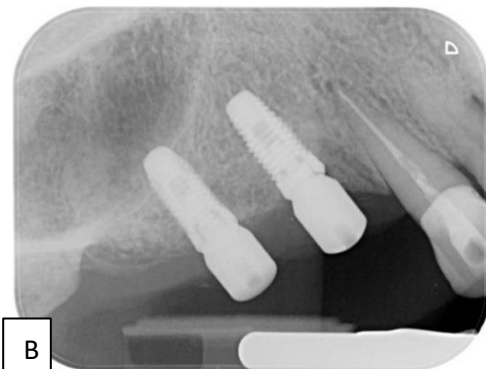
**Fig. 9.** Slim abutments placement and suture.



**Fig. 10.** Tissue healing after four weeks.



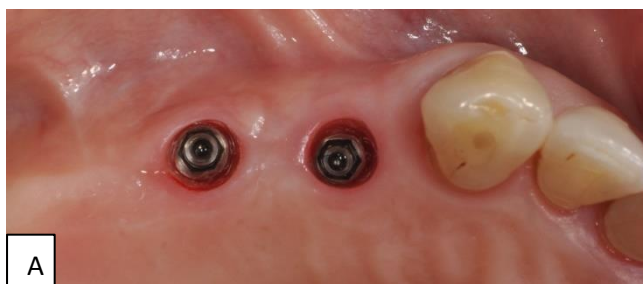
A



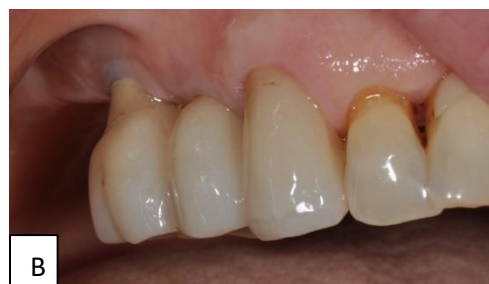B

**Fig. 11.** A): replacement of slim abutment with larger diameter abutments; B): follow-up X-ray, bone regeneration with new sinus cortical position can be seen.

Subsequently, a conventional impression was taken to fabricate metal-ceramic crowns (Fig.12a, b). At a follow-up ranging from 13 to 43 months, all patients were recalled for a control X-ray (Fig. 13). The primary outcome of the effectiveness of the Rialto technique was considered to be the bone gain within the maxillary sinus between the initial surgery and the 13-43 month follow-up (obtained as the difference between the VBH values measured between the initial surgery and the 13-43 month follow-up). The number of sinus mucosa perforations was considered the primary safety outcome, and the incidence of benign paroxysmal positional vertigo (BPPV) was regarded as the secondary safety outcome.

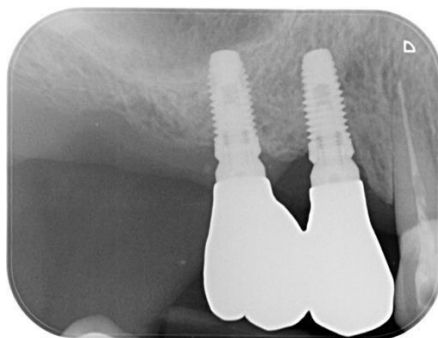


A



B

**Fig. 12.** A): occlusal view of the mucosal pathway and the increase in soft tissue at the vestibular level of 14; B): appearance of the final prosthesis on delivery.



**Fig. 13.** Follow-up X-ray at 16 months.

In the descriptive statistical analysis, continuous quantitative variables were summarized using mean and standard deviation. Where the mean was not representative of the distribution, with the median and the 25th and 75th percentiles, categorical variables were summarized using absolute frequencies and percentages. Differences between median values at different time points were tested using the non-parametric Wilcoxon test. The level of statistical significance was set at  $\alpha < 0.05$ . The statistical analysis was conducted using the IBM Statistical Package for Social Science (SPSS) software version 25.

## RESULTS

In this exploratory study, 20 patients with a median age of 64 years (25th-75th percentile, 20 years-72 years) were recruited, with 8 (40%) female patients and 12 (60%) male patients.

### *Efficacy*

The median values of vertical bone height (VBH) significantly increased between the first surgery (median 6 mm; 25th-75th percentile, 5 mm - 6 mm) and the follow-up period, which lasted from 13 to 43 months (median 9 mm; 25th-75th percentile, 8 mm - 9 mm). Median bone gain at follow-up was 3 mm (25th-75th percentile, 2 mm - 3 mm) (Wilcoxon rank-sum test:  $Z = -3.985$ ,  $p < 0.001$ ).

### *Safety*

No cases of sinus membrane perforations were detected. No patients reported benign paroxysmal positional vertigo (BPPV).

## DISCUSSION

The transcresal technique using osteotomies, like any other surgical procedure, has undergone modifications to achieve greater simplicity, higher success rates, fewer complications, and less discomfort for the patient. The initial changes were planned to accelerate the procedure, simplify the fracture of the sinus floor cortical bone, avoid the use of a mallet, and minimize the percentage of sinus membrane injuries (18-50).

In this study, we evaluated bone regeneration within the maxillary sinus using only a blood clot and collagen sheets in 20 transcresal sinus lifts performed on 20 patients using the atraumatic "Rialto" technique. We also assessed the most common intraoperative complications associated with the use of osteotomies, such as sinus membrane perforation and BPPV (19).

The height of the initial bone crest (RBH) is essential for both implant survival and the percentage of membrane perforations. Many authors consider a residual bone height of at least 4-5 mm as a clinical indication for the transcresal technique (20). A review based on 19 studies using the osteotome technique demonstrated a survival rate of 95% after 5 years. However, the most significant difference was observed between implants placed in residual bone height (RBH)  $< 5$  mm, which showed a survival rate of 92%, compared to 96% for implants placed in bone with a height  $\geq 5$  mm. Furthermore, the authors concluded that using filling materials was irrelevant to implant survival (21). The results of our

study are consistent with the literature data, with a median bone regeneration of 3 mm (25th-75th percentile, 2 mm-3 mm) with RBH  $\geq$  5 mm and a 100% survival rate at a prosthetic follow-up ranging from 13 to 43 months.

Using a biomaterial inside the maxillary sinus with the crestal technique is still a subject of discussion. Studies comparing transcresal sinus lift surgery with osteotomes with or without using bone graft materials and systematic literature reviews have not reported significant differences in implant survival and success rates (22, 23).

Nedir et al., in a study on 17 patients and 25 implants placed using the osteotome technique without filling material, reported an average bone regeneration inside the sinuses of  $3.1 \pm 1.5$  mm and no implant failure after 3 years of prosthetic loading (24). Volpe et al. (25) observed no implant failures and an average increase in VBH of  $2.8 \pm 1.1$  mm after 11-32 months of prosthetic loading in 29 implants placed in 20 patients. The subantral space created by elevating the Schneider membrane and supported by the implant fills with a stable clot that will mature to form new bone. The biological basis for the formation of new bone beneath the sinus mucosa follows the principles of bone regeneration, as occurs, for example, in healing in post-extraction sockets (26, 27). The blood clot induces the growth, proliferation, and differentiation of various types of cells, stimulating angiogenesis and new bone formation. The tent effect created by the implant beneath the mucosa triggers a process reminiscent of the principles of GBR (28, 29).

In 2006, Palma et al. (14) were the first to histologically demonstrate bone regeneration beneath the sinus mucosa supported by implants without filling materials. The authors concluded that the membrane plays a fundamental role in regeneration for its intrinsic properties and as a barrier protecting the clot.

However, in a subsequent study using the same animal model, it was observed that bone regeneration starts from the floor of the maxillary sinus. In contrast, it was not observed in conjunction with the sinus membrane after 10 days of healing (31). Scala et al. state that simultaneous implant placement plays a key role in bone regeneration within the maxillary sinuses when no filler is used. In a histological study on monkeys, they demonstrate that during the first 20 days following surgery, the sinus membrane does not participate in the regenerative process and that the input comes from the floor of the sinus and the bone chips brought into the maxillary sinus by the implant during its placement (32).

Based on this concept, the multi-cutting HS drill was designed to collect and retain bone fragments during socket preparation and the maxillary sinus cortical bone erosion. Subsequently, the bone is inserted with collagen into the space created inside the sinus cavity. An interesting finding frequently observed when no filler materials are used is direct contact between the implant apices and the sinus mucosa after approximately 3-4 months of healing.

Volpe et al. (33), in a retrospective study using a transcresal technique with an osteotome without graft material but only with the use of collagen, immediately after the surgical procedure, the average membrane elevation was  $3.8 \pm 1.1$  mm, while at follow-up after 5-13 years of loading, the average regeneration was  $2.4 \pm 1.4$ . Still, the new position of the maxillary sinus cortical bone was clearly evident.

Similar results have been found in this group of patients. The initial millimeter of slight radiopacity above the apex of the implant, present immediately after surgery, is presumably due to collagen and blood interposed between the implant and the sinus mucosa. During healing, membrane movements prevent clot stabilization and, consequently, the formation of new bone above the implant apices.

M. Jungner et al. (34), in a follow-up study on cases of maxillary sinus floor augmentation with a lateral technique, CBCT detected that implant apices often protrude through the grafted area but are covered by a healthy sinus membrane. Even maxillary sinuses filled with autologous bone have a resorption during the first months of healing. Johansson et al. (35) found a resorption rate of bone grafts taken from the iliac crest of 47% in the first 6 months of healing and implant apices in contact with the sinus mucosa. However, no conclusive data in the literature reporting the possible advantage and maturation of a bone graft in the apical portion of the implant (36).

In the past, membrane perforation was the most frequent complication encountered with the transcresal technique. Today, with the introduction of new, increasingly atraumatic burs and inserts, we have a decrease in the percentage of perforations of 3.8%. Sang-Hoon Ahn et al. (38) performed 391 maxillary sinus floor elevations with specific reamers for site preparation and simultaneous implant placement in 380 patients.

Eighteen (4.6%) perforations of the Schneider membrane occurred, and the 2-year survival rate was 95.4%. The success rate was 92.7% in sites with a sinus floor  $<$  4 mm and 96.4% in sites with bone height  $>$  4 mm. None of the patients experienced any discomfort during the procedure.

Trombelli L. et al. performed 30 transcresal sinus lifts using the "Smart Lift" technique, which is based on a sequence of manual drills and elevators. They encountered only one perforation with the Valsalva maneuver immediately after fracturing the sinus cortical bone (39).

The difficulty with all crestal sinus lift techniques is controlling the integrity of the membrane throughout the entire lifting process. Perforation can occur at any stage of the procedure, from fracturing the floor of the maxillary sinus to detaching and lifting the membrane to graft insertion and finally during implant placement. Garbacea et al. (40)



macroscopically investigated sinus membrane perforation during surgery using three transcresal sinus floor elevation techniques. Intact maxillary sinuses from twenty human cadavers were used for the study. Real-time sinus endoscopy images, periapical digital radiographs, and cone-beam computed tomography (CBCT) were used to evaluate the outcome of each surgical procedure.

No statistically significant differences were found in the perforation rate among the three surgical techniques. Endoscopy showed a higher frequency of perforations during implant placement compared to instrumentation or graft insertion in all three techniques. This pilot study demonstrated that sinus membrane perforation can occur at any time during the sinus lift procedure, regardless of the surgical technique used. The particular design of the multi-cutting drill (with  $\varnothing$  2.8-3.2-4.2 with 18 cutting edges along the axis of the drill for 3 mm and 6 cutting edges at the tip) allows for controlled erosion of the cortical floor of the maxillary sinus, exposing the membrane without damaging it. Mucosal elevation is the most delicate moment of the procedure. Various techniques have been devised to detach the sinus mucosa from the sinus floor.

Kao DW et al. (41) used an uncontrolled water jet pressure from a plastic syringe that did not allow for equal distribution of hydraulic pressure on the membrane, and it was not uniformly lifted as fluids flowed from the crestal osteotomy. In this regard, screw elevators have been developed that are inserted through the alveolar crest into the maxillary sinus to seal the osteotomy and allow for direct fluid passage to the Schneiderian membrane (42).

Pommer et al. (43), in an *in vitro* study on 20 human cadaver sinuses, demonstrated that the Schneiderian membrane can be stretched up to 132.6% of its original unidimensional size and up to 124.7% bidimensionally.

The Authors argue that in the elevation of the sinus floor by the crestal approach, a correct circumferential detachment of the membrane before its elevation is crucial to reduce tensions and decrease the risk of perforations. With the sinus lift detachors included in the Rialto kit, it is possible to elevate the membrane to create a space that can accommodate a potential bone substitute or collagen alone. In our procedure, the initial detachment of the membrane is performed with the external and internal elevators at a 60° angle, with the interposition of small collagen leaflets between the membrane and the manual instruments, using a gentle movement similar to the lateral window procedure.

Subsequently, collagen is added with the "rounded sinus lift detachor" until the desired height is reached. The use of collagen prevents direct contact between the membrane and the instruments and, subsequently, contact with the apex of the implant. Furthermore, through these manual instruments, tension reduction is achieved at the margins where the membrane is still attached to the floor of the maxillary sinus. To avoid perforations during implant placement, we raise the sinus mucosa approximately 1 mm higher, using manual instruments equipped with stops, compared to the part of the implant that will be inserted into the sinus. This technique prevents further stress on the mucosa during implant placement, which we believe is the cause of perforations noted by Garbacea et al. (44) through endoscopy.

In our study, the integrity of the mucosa was evaluated with the Valsalva maneuver at each surgical step, both for the sequence of drills and manual instruments, and we did not find any lesions. To achieve these results, a careful pre-surgical study of the sinus anatomy is important: the absence of septa, oblique walls in the sinus lift area, and residual bone height  $\geq 4$  mm (45).

Reiser et al. (46) identified sinus anatomy as a possible etiology of perforations. These authors examined the membrane response to BAOSFE in human cadavers. Of the 25 sites treated with implant insertion, 6 showed perforations, with a rate of 24%. Between these 6, 4 perforations were associated with the proximity of the osteotomy to the antral septa or mesio-vestibular wall. The same principle is added to a high risk of transcresal perforation in sites with oblique sinus floors. Another complication is benign paroxysmal positional vertigo (BPPV), which has been reported following the use of osteotomies. Symptoms include dizziness or vertigo, loss of balance, and nausea. Several authors have hypothesized that the factors responsible for BPPV following crestal surgery may be the percussive force exerted on the maxilla by osteotomies and head hypertension during surgery (47).

Di Girolamo M. et al. (48) hypothesized that percussion with a hammer on osteotomes causes percussive forces that detach heavy inorganic particles (otoliths) from the otoconial layer of the utricular macula. The use of HS multitoothed drills, with depth stops, eliminates the percussive forces generated by the hammer on the osteotomes, thus avoiding the annoying sensation that patients report during surgery and the related complication of BPPV. In our study, no patient complained of benign paroxysmal positional vertigo. In conclusion, the Rialto technique is based on the concept of bone regeneration and simultaneous osseointegration. The specially designed multitoothed bur exposes the sinus mucosa and retains bone to be reused as filling material without showing any adverse effects. The sequence of intrasinus scalers allows for the gentle detachment of the mucosa from the sinus floor, reducing tension during its lifting, as occurs with the lateral window technique (49, 50).

## CONCLUSIONS

The results of our study confirm that bone formation within the maxillary sinus occurs when using a collagen sponge in combination with the transcrestal "Rialto" technique. This technique is minimally invasive and reduces the most common complications, such as perforation of the sinus mucosa, benign paroxysmal positional vertigo (BPPV), and discomfort for the patient, and can be combined with any type of implant used.

## REFERENCES

1. Boyne Pj, Ra J. Grafting of the maxillary sinus floor with autogenous marrow and bone. *J Oral Surg.* 1980;38(8):613-616.
2. Pjetursson BE, Rast C, Brägger U, Schmidlin K, Zwahlen M, Lang NP. Maxillary sinus floor elevation using the (transalveolar) osteotome technique with or without grafting material. Part I: implant survival and patients' perception. *Clinical Oral Implants Research.* 2009;20(7):667-676. doi:<https://doi.org/10.1111/j.1600-0501.2009.01704.x>
3. Jensen OT, Shulman LB, Block MS, Iacono VJ. Report of the Sinus Consensus Conference of 1996. *The International Journal of Oral & Maxillofacial Implants.* 1998;13 Suppl:11-45.
4. Block MS. Improvements in the Crestal Osteotome Approach Have Decreased the Need for the Lateral Window Approach to Augment the Maxilla. *Journal of Oral and Maxillofacial Surgery.* 2016;74(11):2169-2181. doi:<https://doi.org/10.1016/j.joms.2016.06.008>
5. Sonoda T, Yamamichi K, Harada T, Yamamichi N. Effect of staged crestal maxillary sinus augmentation: A case series. *Journal of Periodontology.* 2019;91(2):194-201. doi:<https://doi.org/10.1002/jper.18-0632>
6. Tatum H. Maxillary and sinus implant reconstructions. *Dental Clinics of North America.* 1986;30(2):207-229.
7. Summers RB. A new concept in maxillary implant surgery: the osteotome technique. *Compendium (Newtown, Pa).* 1994;15(2):152, 154-156, 158 passim; quiz 162.
8. Zitzmann NU, Schärer P. Sinus elevation procedures in the resorbed posterior maxilla. *Oral Surgery, Oral Medicine, Oral Pathology, Oral Radiology, and Endodontology.* 1998;85(1):8-17. doi:[https://doi.org/10.1016/s1079-2104\(98\)90391-2](https://doi.org/10.1016/s1079-2104(98)90391-2)
9. Engelke W, Deckwer I. Endoscopically controlled sinus floor augmentation. A preliminary report. *Clinical Oral Implants Research.* 1997;8(6):527-531. doi:<https://doi.org/10.1034/j.1600-0501.1997.080612.x>
10. Rosen PS, Summers R, Mellado JR, et al. The bone-added osteotome sinus floor elevation technique: multicenter retrospective report of consecutively treated patients. *The International Journal of Oral & Maxillofacial Implants.* 1999;14(6):853-858.
11. Stacchi C, Bernardello F, Spinato S, et al. Intraoperative complications and early implant failure after transcrestal sinus floor elevation with residual bone height  $\leq 5$  mm: A retrospective multicenter study. *Clinical Oral Implants Research.* 2022;33(8):783-791. doi:<https://doi.org/10.1111/clr.13959>
12. Sammartino G, Mariniello M, Scaravilli MS. Benign paroxysmal positional vertigo following closed sinus floor elevation procedure: mallet osteotomes vs. screwable osteotomes. A triple blind randomized controlled trial. *Clinical Oral Implants Research.* 2010;22(6):669-672. doi:<https://doi.org/10.1111/j.1600-0501.2010.01998.x>
13. Lundgren S, Andersson S, Lars Sennerby. Spontaneous Bone Formation in the Maxillary Sinus after Removal of a Cyst: Coincidence or Consequence? *Clinical Implant Dentistry and Related Research.* 2003;5(2):78-81. doi:<https://doi.org/10.1111/j.1708-8208.2003.tb00187.x>
14. Palma VC, Magro-Filho O, De Oliveria JA, Lundgren S, Salata LA, Sennerby L. Bone Reformation and Implant Integration following Maxillary Sinus Membrane Elevation: An Experimental Study in Primates. *Clinical Implant Dentistry and Related Research.* 2006;8(1):11-24. doi:<https://doi.org/10.2310/j.6480.2005.00026.x>
15. Lundgren S, Anderson S, Gualini F, Sennerby L. Bone Reformation with Sinus Membrane Elevation: A New Surgical Technique for Maxillary Sinus Floor Augmentation. *Clinical Implant Dentistry and Related Research.* 2004;6(3):165-173. doi:<https://doi.org/10.1111/j.1708-8208.2004.tb00217.x>
16. Del Fabbro M, Corbella S, Weinstein T, Ceresoli V, Taschieri S. Implant Survival Rates after Osteotome-Mediated Maxillary Sinus Augmentation: A Systematic Review. *Clinical Implant Dentistry and Related Research.* 2011;14:e159-e168. doi:<https://doi.org/10.1111/j.1708-8208.2011.00399.x>
17. Pjetursson BE, Ignjatovic D, Matulienė G, Brägger U, Schmidlin K, Lang NP. Transalveolar maxillary sinus floor elevation using osteotomes with or without grafting material. Part II: Radiographic tissue remodeling. *Clinical Oral Implants Research.* 2009;20(7):677-683. doi:<https://doi.org/10.1111/j.1600-0501.2009.01721.x>
18. Davarpanah M, Martinez H, Tecucianu JF, Hage G, Lazzara R. The modified osteotome technique. *The International journal of periodontics & restorative dentistry.* 2001;21(6):599-607.
19. Călin C, Petre A, Drafta S. Osteotome-Mediated Sinus Floor Elevation: A Systematic Review and Meta-Analysis. *The International Journal of Oral & Maxillofacial Implants.* 2014;29(3):558-576. doi:<https://doi.org/10.11607/jomi.3206>
20. Hsu Y, Rosen PS, Choksi K, Shih M, Ninneman S, Lee C. Complications of sinus floor elevation procedure and

- management strategies: A systematic review. *Clinical Implant Dentistry and Related Research*. 2022;24(6):740-765. doi:<https://doi.org/10.1111/cid.13086>
21. Bae OY, Kim YS, Shin SY, Kim WK, Lee YK, Kim SH. Clinical Outcomes of Reamer- vs Osteotome-Mediated Sinus Floor Elevation with Simultaneous Implant Placement: A 2-Year Retrospective Study. *The International Journal of Oral & Maxillofacial Implants*. 2015;30(4):925-930. doi:<https://doi.org/10.11607/jomi.3779>
  22. Si M, Zhuang L, Gu YX, Mo J, Qiao S, Lai HC. Osteotome sinus floor elevation with or without grafting: a 3-year randomized controlled clinical trial. *Journal of Clinical Periodontology*. 2013;40(4):396-403. doi:<https://doi.org/10.1111/jcpe.12066>
  23. Taschieri S, Corbella S, Saita M, Tsesis I, Del Fabbro M. Osteotome-Mediated Sinus Lift without Grafting Material: A Review of Literature and a Technique Proposal. *International Journal of Dentistry*. 2012;2012:849093. doi:<https://doi.org/10.1155/2012/849093>
  24. Nedir R, Bischof M, Vazquez L, Nurdin N, Szmukler-Moncler S, Bernard JP. Osteotome sinus floor elevation technique without grafting material: 3-year results of a prospective pilot study. *Clinical Oral Implants Research*. 2009;20(7):701-707. doi:<https://doi.org/10.1111/j.1600-0501.2008.01696.x>
  25. Volpe S, Lanza M, Verrocchi D, Sennerby L. Clinical Outcomes of an Osteotome Technique and Simultaneous Placement of Neoss Implants in the Posterior Maxilla. *Clinical Implant Dentistry and Related Research*. 2011;15(1):22-28. doi:<https://doi.org/10.1111/j.1708-8208.2011.00378.x>
  26. Di Girolamo M, Barlattani A, Grazzini F, et al. Healing of the post extractive socket: technique for conservation of alveolar crest by a coronal seal. *Journal of Biological Regulators and Homeostatic Agents*. 2019;33(6 Suppl. 1):125-135. DENTAL SUPPLEMENT.
  27. Di Girolamo M, Arullani CA, Calcaterra R, Manzi J, Arcuri C, Baggi L. Preservation of extraction socket in immediate implant placement: a clinical study. *Oral Implantol (Rome)*. 2017;9(4):222-232. doi:<https://doi.org/10.11138/orl/2016.9.4.222>
  28. Lang N, Araújo M, Karring T. Alveolar Bone Formation. In: *Clinical Periodontology and Implant Dentistry*. Blackwell Publishing; 2003:866-896.
  29. Dahlin C, Linde A, Gottlow J, Nyman S. Healing of bone defects by guided tissue regeneration. *Plastic and Reconstructive Surgery*. 1988;81(5):672-676. doi:<https://doi.org/10.1097/00006534-198805000-00004>
  30. Cricchio G, Canavarras Palma V, Faria PEP, et al. Histological Findings Following the Use of a Space-Making Device for Bone Reformation and Implant Integration in the Maxillary Sinus of Primates. *Clin Implant Dent Relat Res*. 2009;11:e14-e22. doi:<https://doi.org/10.1111/j.1708-8208.2009.00158.x>
  31. Jungner M, Cricchio G, Salata LA, et al. On the Early Mechanisms of Bone Formation after Maxillary Sinus Membrane Elevation: An Experimental Histological and Immunohistochemical Study. *Clinical Implant Dentistry and Related Research*. 2014;17(6):1092-1102. doi:<https://doi.org/10.1111/cid.12218>
  32. Scala A, Botticelli D, Rangel IG, De Oliveira JA, Okamoto R, Lang NP. Early healing after elevation of the maxillary sinus floor applying a lateral access: a histological study in monkeys. *Clinical Oral Implants Research*. 2010;21(12):1320-1326. doi:<https://doi.org/10.1111/j.1600-0501.2010.01964.x>
  33. Volpe S, Michele Di Girolamo, Paolo Pagliani, Zicari S, Lars Sennerby. Osteotome-Induced Blood Clot and Subsequent Bone Formation with the Use of Collagen Sponge for Integration of Single Dental Implants into the Atrophied Posterior Maxilla: A Retrospective Follow-Up of 36 Implants after 5 to 13 years. *Int J Dent*. 2022;2022:1-8. doi:<https://doi.org/10.1155/2022/6594279>
  34. Jungner M, Legrell P, Lundgren S. Follow-up Study of Implants with Turned or Oxidized Surfaces Placed After Sinus Augmentation. *The International Journal of Oral & Maxillofacial Implants*. 2014;29(6):1380-1387. doi:<https://doi.org/10.11607/jomi.3629>
  35. Johansson LÅ, Isaksson S, Lindh C, Becktor JP, Sennerby L. Maxillary Sinus Floor Augmentation and Simultaneous Implant Placement Using Locally Harvested Autogenous Bone Chips and Bone Debris: A Prospective Clinical Study. *Journal of Oral and Maxillofacial Surgery*. 2010;68(4):837-844. doi:<https://doi.org/10.1016/j.joms.2009.07.093>
  36. Artzi Z, Parson A, Nemcovsky CE. Wide-diameter implant placement and internal sinus membrane elevation in the immediate postextraction phase: clinical and radiographic observations in 12 consecutive molar sites. *The International journal of oral & maxillofacial implants*. 2003;18(2):242-249.
  37. Tan WC, Lang NP, Zwahlen M, Pjetursson BE. A systematic review of the success of sinus floor elevation and survival of implants inserted in combination with sinus floor elevation Part II: Transalveolar technique. *Journal of Clinical Periodontology*. 2008;35(8Suppl):241-254. doi:<https://doi.org/10.1111/j.1600-051x.2008.01273.x>
  38. Ahn SH, Park EJ, Kim ES. Reamer-mediated transalveolar sinus floor elevation without osteotome and simultaneous implant placement in the maxillary molar area: clinical outcomes of 391 implants in 380 patients. *Clinical Oral Implants Research*. 2011;23(7):866-872. doi:<https://doi.org/10.1111/j.1600-0501.2011.02216.x>
  39. Trombelli L, Minenna P, Franceschetti G, Farina R, Minenna L. Smart-Lift: una procedura minimamente invasiva per l'elevazione del seno mascellare. *Clinica e Ricerca Implantologia*. 2008;76(7):73-86.
  40. Garbacea A, Lozada JL, Church CA, et al. The Incidence of Maxillary Sinus Membrane Perforation During Endoscopically Assessed Crestal Sinus Floor Elevation: A Pilot Study. *Journal of Oral Implantology*. 2012;38(4):345-359. doi:<https://doi.org/10.1563/aid-joi-d-12-00083>

41. Kao DWK, DeHaven HA. Controlled Hydrostatic Sinus Elevation: A Novel Method of Elevating the Sinus Membrane. *Implant Dentistry*. 2011;20(6):425-429. doi:<https://doi.org/10.1097/id.0b013e3182365307>
42. Sentineri R, Dagnino G. Sinus augmentation by crestal approach with the Sinus Physiollift device. *Implants*. 2011;1:13-17.
43. Pommer B, Unger E, Sütö D, Hack N, Watzek G. Mechanical properties of the Schneiderian membrane *in vitro*. *Clinical Oral Implants Research*. 2009;20(6). doi:<https://doi.org/10.1111/j.1600-0501.2008.01686.x>
44. Chan HL, Oh TJ, Fu JH, Benavides E, Avila-Ortiz G, Wang HL. Sinus augmentation via transcresal approach: a comparison between the balloon and osteotome technique in a cadaver study. *Clinical Oral Implants Research*. 2012;24(9):n/a-n/a. doi:<https://doi.org/10.1111/j.1600-0501.2012.02506.x>
45. Kato S, Omori Y, Kanayama M, et al. Sinus Mucosa Thickness Changes and Ostium Involvement after Maxillary Sinus Floor Elevation in Sinus with Septa. A Cone Beam Computed Tomography Study. *Dentistry Journal*. 2021;9(8):82. doi:<https://doi.org/10.3390/dj9080082>
46. Reiser GM, Rabinovitz Z, Bruno J, Damoulis PD, Griffin TJ. Evaluation of maxillary sinus membrane response following elevation with the crestal osteotome technique in human cadavers. *Int J Oral Maxillofac Implants*. 2002;16(6):833-840.
47. Peñarrocha-Diago M, Rambla-Ferrer J, Perez V, Pérez-Garrigues H. Benign paroxysmal vertigo secondary to placement of maxillary implants using the alveolar expansion technique with osteotomes: a study of 4 cases. *The International journal of oral & maxillofacial implants*. 2008;23(1):129-132.
48. Girolamo M, Napolitano B, Arullani CA, Bruno E, Girolamo S. Paroxysmal positional vertigo as a complication of osteotome sinus floor elevation. *European Archives of Oto-Rhino-Laryngology*. 2005;262(8):631-633. doi:<https://doi.org/10.1007/s00405-004-0879-9>
49. Candotto V, Gallusi G, Piva A, Baldoni M, Di Girolamo M. Complications in sinus lift. *Journal of Biological Regulators and Homeostatic Agents*. 2020;34(1 Suppl. 1):139-142. DENTAL SUPPLEMENT.
50. Di Girolamo S, Martino F, Guerrieri M, et al. Odontogenic Maxillary Sinusopathies: a Radiological Classification. *Journal of Maxillofacial and Oral Surgery*. 2020;21(1). doi:<https://doi.org/10.1007/s12663-020-01329-8>