

# A fully digital rehabilitation for immediately loaded fixed in-terim complete-arch prosthesis: A case report



Corresponding Author

**G. Ruggiero**

Scientific Unit of Digital Dentistry (SUDD), Department of Neurosciences, Reproductive and Odontostomatological Sciences, University Federico II of Napoli, 80131 Napoli, NA, Italy

## Abstract

The digital workflows in implantology are becoming increasingly common, offering rehabilitation with predictable outcomes. However, there are instances where a fully digital workflow is not feasible, often requiring conventional methods such as when registering the patient's occlusion. The present paper aimed to show a case report based on a digital workflow to make immediately loaded fixed interim complete-arch prostheses for a patient with terminal dentition. The key innovation lies in digitally capturing the patient's maxillo-mandibular relationship, prior to the surgical procedure, by utilizing two dedicated "skeletal scan bodies" (ScanSke) and an intraoral scanner. These ScanSke were used as reference landmarks screwed onto mini-implants. In particular, these scan bodies were scanned with the maxillary complete arch before and after implant surgery, in order to be used as reference landmarks for the superimposition of the arches before and after the implant placement, maintaining the maxillary relationship with the antagonist arch.

## Authors

**Marco Serri<sup>2</sup>,**  
**Michele Serri<sup>2</sup>,**  
**A. Mastro Simone<sup>1</sup>,**  
**F. Zarone<sup>1</sup>,**  
**R. Sorrentino<sup>1</sup>**

<sup>1</sup>  
Scientific Unit of Digital Dentistry (SUDD), Department of Neurosciences, Reproductive and Odontostomatological Sciences, University Federico II of Napoli, 80131 Napoli, NA, Italy

<sup>2</sup>  
Private Activity, Studio Serri Odontoiatria e Salute SRL, Via Monsignor Virgilio Angioni 64, Quartu S.Elena, 09045, Cagliari, Italy

## Keywords

Digital dentistry; implant rehabilitation; digital workflow; complete-arch prostheses; dental occlusion; digital occlusion; occlusion recording; digital occlusal relationship; immediate loading; vertical dimension occlusion

## DOI

10.23805/JO.2024.661

## INTRODUCTION

Over the past few decades, the widespread integration of digital technologies in dentistry, coupled with the introduction of increasingly advanced and attractive restorative materials, has ushered in a profound shift in prosthetic approaches. Specifically, intraoral scanners (IOSs) are rapidly gaining prominence in daily dental practice [1], primarily due to a range of indisputable benefits. Patients overwhelmingly prefer scans over conventional impressions, significantly reducing stress and discomfort [2]. Additionally, intraoral scanners simplify and expedite clinical procedures [3-4], are unaffected by dimensional changes in impression materials and gypsum [2, 5], enhance communication within the dental team, with the laboratory, and with the patient [4, 6], and obviate the need for storing and disposing of casts [7].

In implantology, the use of digital technologies has expanded an interesting scenario in which the use of these technologies is increasingly frequent, thanks to accurate planning, and faster, easier, and more predictable surgery [8].

During the prosthetic fabrication phase, it is feasible to virtually replicate the implant position through intraoral scanning [9] which prevents distortions caused by traditional impression materials, enhances patient comfort, and eliminates the necessity of a gypsum cast [10].

Nevertheless, in edentulous patients, restoring aesthetics and chewing function through fixed implant-supported prostheses seems to be a highly effective means of enhancing their quality of life [11-12]. Recent years have witnessed a wealth of clinical studies and systematic reviews affirming that early and immediate functional loading of dental implants can be equally effective as treatments following conventional loading protocols [11,13-14]. Immediate loading offers various advantages, including time reduction, elimination of temporary removable prostheses, avoidance of secondary surgeries, and preservation of residual alveolar ridges [15-16]. The application of digital technologies has further advanced the rehabilitation of fully edentulous patients through the utilization of complete-arch fixed prostheses supported by multiple implants.

Digital technologies like intraoral scanners and computer-aided design / computer-aided manufacturing (CAD-CAM), coupled with the accessibility of innovative prosthetic materials, make the implementation of the immediate-loading protocol feasible [17-18]. This results in a significant reduction in procedural times, heightened patient satisfaction, and the attainment of favorable aesthetic outcomes [19-20].

In traditional protocols executed in a hybrid digital/analog workflow, it is the clinician's responsibility to register the patient's occlusion in a rather empirical manner using cutaneous reference points and the

interposition of a wax rim. This means that along the digital workflow, it becomes necessary to insert at least one "analog" phase for recording the occlusion.

Several papers are present in the literature regarding systems for recording the maxillomandibular relationship in complete-arch implant-supported restoration, such as custom scanning devices, useful both for intraoral scanning and maxillo-mandibular relationship registration [21], or fiducial markers which in addition to facilitating the stitching algorithm of scanning, allows an accurate overlapping of scans [22-26]. Also noteworthy is the use of pins positioned before surgery to be used as references for the superimpositions of the scanning surfaces after surgery [27]. Unfortunately, to date, a completely digital operating protocol that would allow avoiding the interposition of at least one analog phase, in a digital operating flow, has not been unanimously defined in the scientific literature.

The present paper aimed to report a clinical case of an immediately loaded fixed interim complete-arch prosthesis for terminal dentition, where the digital registration of the patient's occlusion takes place prior to the surgical procedure.

## CASE REPORT

The patient enrolled in the present case report is a 64-year-old male, treated during the private activity at Studio Dentistico Serri, Quartu Sant'Elena, Cagliari (Italy) in February 2023. He was provided with detailed explanations of the clinical protocol and subsequently signed informed consent forms. According to the American Society of Anesthesiologists (ASA) classification, the patient was an ASA I, with good oral hygiene, and smoking less than 10 cigarettes/day. He presented, adequate bone volume for implant placement, class I to III bone quality according to Lekholm and Zarb [28], and sufficient prosthetic space for receiving an anatomic restoration. Moreover, no infection at the implant sites was detected.

### 2.1 Surgical interventions

Standardized cone beam computed tomography radiographs and clinical photographs of the restorations were made. In particular, pre-surgical x-rays (orthopantomography and cone beam computed tomography) and photos were carried out from a few days up to 2 months before surgery (Figure 1).

The present clinical technique was based on the use of dedicated skeletal scan bodies and mini-implants, conceived by Dr. Marco Serri, which exhibited distinct characteristics. Customized for either the right or left side of the dental arch's distal sections, these scan bodies showed an irregular parallelepiped shape with rounded edges on one side and three facets at a 45° angle on the other. Fabricated from polyether-etherketone (PEEK), these scan bodies were designed to be

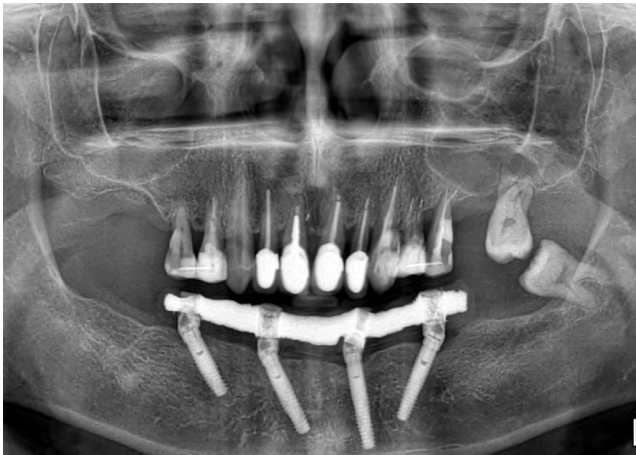

Fig. 1A

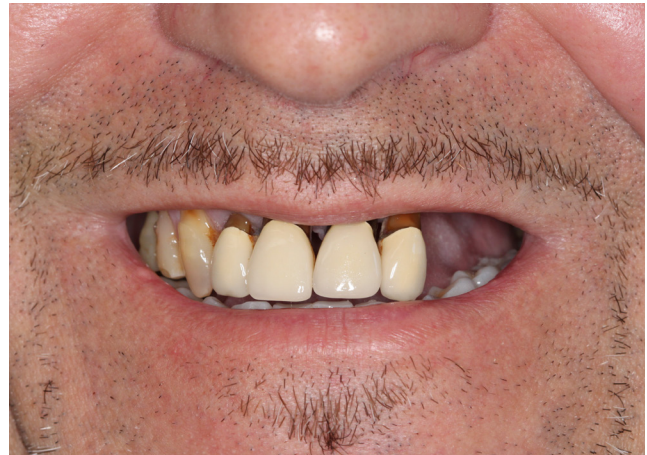

Fig. 1B

used during the implant placements. The contralateral skeletal scan bodies differed on their occlusal surfaces, featuring a hemisphere on one side and the letter L on the left skeletal scan body. This unique design, coupled with specific positioning on either side, ensured that the scanner identified the external surfaces of the skeletal scan bodies as distinct entities, as illustrated in Figure 2. Therefore, intraoral scans were performed according to the proposed clinical approach:

1. First acquisition:
  - › Pre-surgical scan of the arch in terminal dentition and the skeletal scan bodies placed (Figure 3);
  - › the opposite arch;
  - › the occlusion.
2. Second acquisition: the post-surgical scan of the edentulous arch, after implants positioning, with the skeletal scan bodies and the metal scan bodies joined with a scanning chain (Figure 4).
3. Third acquisition: the post-surgical scan of the edentulous arch after implants positioning, with the

skeletal scan bodies and mucosa (Figure 5).

Once these 3 types of intraoral scans were obtained, the matching of the 3 digitizations was performed thanks to the presence of the skeletal scan bodies (ScanSke); these were transferred to a virtual articulator where the prosthetic space within which the prosthesis was designed was obtained.

## 2.2 Surgical procedures

In this case report, the positioning of implants occurred immediately after the tooth extraction. One hour before surgery, antibiotic prophylaxis (i.e. 1 gr amoxicillin or, if allergic to penicillin, 600 mg clindamycin) was administered and a 0.2% chlorhexidine mouthwash for oral disinfection (twice a day for 15 days) was prescribed [29].

Superficial synchronous electromyography was performed with the Teethan system because this device analyzes the initial patient's occlusal condition, through quantitative data and objective measurements.



Fig. 2A

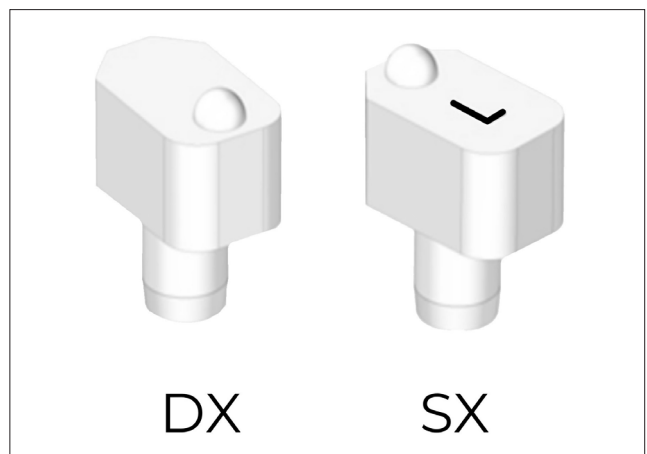


Fig. 2B

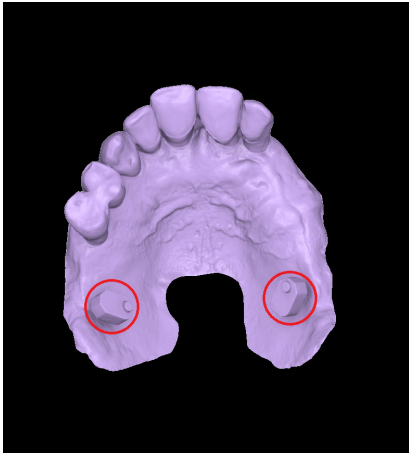

Fig. 3

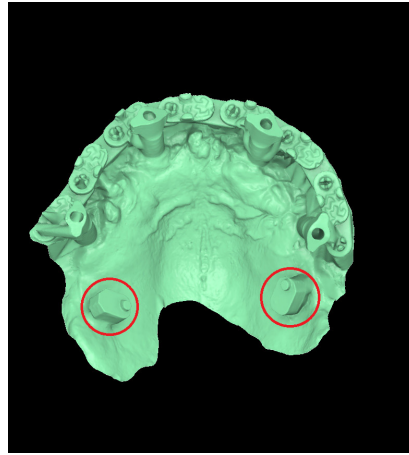


Fig. 4

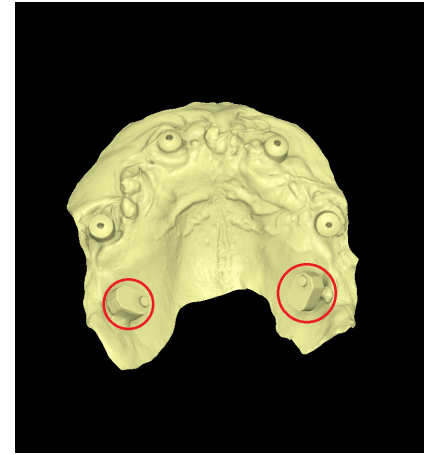


Fig. 5

Before all the extractions, the surgeon placed mini-implants (Figure 2a) and corresponding ScanSke (Figure 2b), therefore, the 2 arches were scanned by using an intraoral scanner, also registering the occlusion. During the surgical session, paracrestal (for edentulous areas) or intrasulcular (for dentate ones) incisions were made under local anesthesia (4% articaine with 1:100,000 epinephrine) [30], followed by the preparation of a mucoperiosteal flap to expose the alveolar bone. The implant positioning was done freehand, therefore, a computer-guided method with surgical guides was not followed. Mattress and force-breaking suture of De Stavola were performed [31]. The patient received 4 endosseous dental implants (Figure 6). Implant diameters were 4.1 mm, while the length varied from 16 in areas 1.2, 1.5 and 2.5, to 14 mm in area 2.2.

Multi-unit abutments (MUA) with conical connection were used to manage the implant angulation. Post-surgical x-rays (orthopantomography and if necessary cone beam computed tomography) were carried out 24 to 36 hours after surgery and three

months after implant placement, in order to check any signs of peri-implant pathology both clinically and radiographically [32].

### 2.3 Prosthetic and laboratory procedures

After surgery, a new scan was performed on the arch where the implants were positioned, using titanium scan bodies joined with a scan chain and ScanSkes (Figure 4). In this way, the following scans were provided to the dental laboratory for superimposition [33]:

1. The one on the pre-surgery jaw with its terminal dentition and the ScanSkes positioned (Figure 3), the occlusion, and the opposite arch;
2. The post-surgery scan, with ScanSkes and scan bodies screwed onto implants (Figure 4);
3. The post-surgery scan on the mucosa with ScanSkes but without titanium scan bodies (Figure 5).

In this way by using a dedicated software the laboratory team superimposed scans from 1. (where there is the registration of the opposite arch and the occlusion), 2.

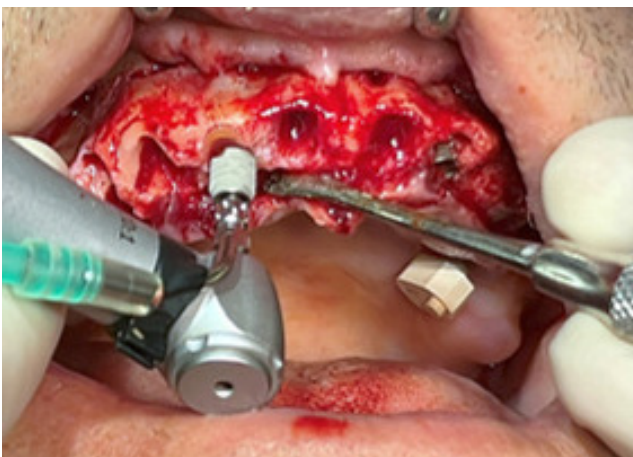

Fig. 6

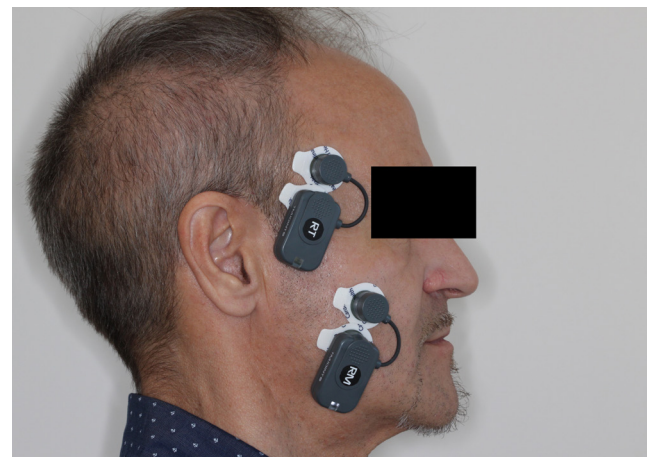

Fig. 7

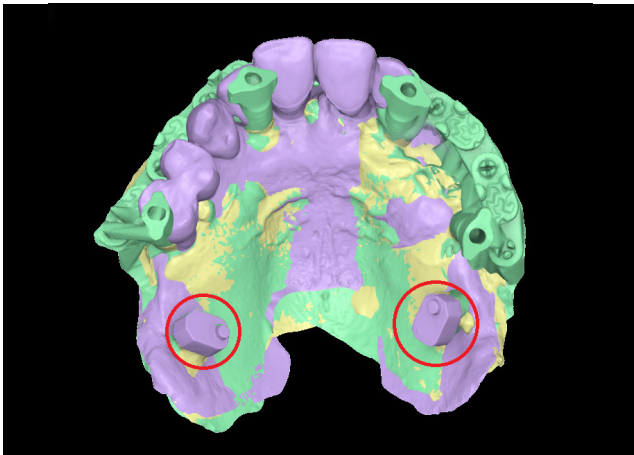


Fig. 8

and 3. (Figure 8), maintaining the occlusal registration detected pre-surgery (Figure 9).

The restoration's color was identified utilizing a traditional shade guide.

After designing the prosthesis on the virtual articulator, both the titanium for the substructure and polymethyl methacrylate (PMMA) for the teeth were milled, all within 24 hours. Dedicated software was used to design the prosthesis (Figure 10).

Therefore, the temporary prosthesis was made with hand-polished titanium on the surface in contact with the mucosa, while the teeth were made of PMMA and then glazed (Figure 11).

#### 2.4 Delivery of restorations

The delivery of the restorations took place 24 hours after surgery (Figure 10) [34]. The implants had prostheses retained by screws, tightened to a torque of 10 N/cm using a dynamometric wrench. Screw channels were filled with polytetrafluoroethylene (PTFE) tape. To ensure proper

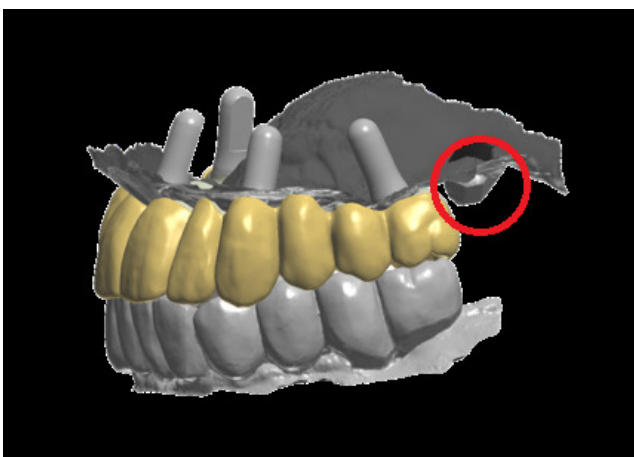


Fig. 10

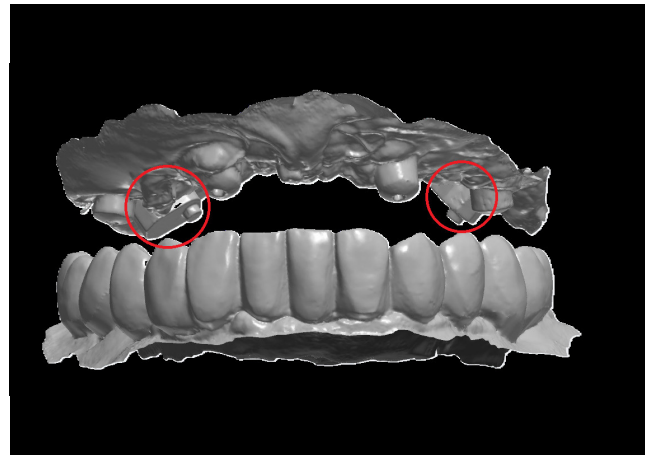


Fig. 9

occlusal contacts and prevent interferences on the restoration, occlusion was assessed by using 8  $\mu$ m thick articulating foil. Any necessary adjustments to occlusion were performed using fine-grit diamond burs, followed by meticulous polishing of the modified surfaces using a dedicated PMMA polishing system. Lastly, comprehensive oral hygiene instructions were given to the patient.

#### 2.5 Follow-up appointments

Seven days after the surgery, the patient came for a follow-up to check the static and dynamic occlusal contacts and adjust them if necessary [35-36]. Two weeks after implant placement, the patient was recalled to remove sutures and control the healing process.

21 days after surgery, superficial synchronous electromyography was performed again, with the Teethan system (Figure 7). The objective was to obtain a functional evaluation of the implant-supported prostheses delivered to the patient [37]. In particular, to observe if there had been an improvement in the occlusal and muscle balance compared to the starting situation.

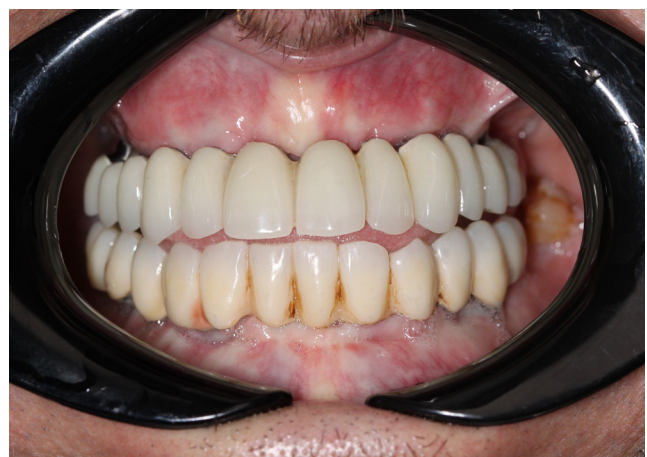

Fig. 11

The analysis made with the Teethan system showed an enhancement of the occlusal stability. In particular, the Global Index of Neuromuscular Balance was improved from an overall value of 64, detected before surgery, to an enhanced value of 87, measured 21 days after surgery [38].

## DISCUSSION

The purpose of the present case report was to describe a fully digital protocol for producing immediately loaded fixed interim complete-arch prostheses for an upper arch in terminal dentition. This approach involves digitally recording the patient's occlusion before the surgical procedure. The process used for occlusal registration could be considered feasible and effective, as the maxillo-mandibular relationship before and after surgery is maintained thanks to the use of dedicated artificial landmarks, the ScanSkEs. This clinical technique would also seem to bring benefit to the patient, as found by the superficial synchronous electromyography system, in which an improvement in post-operative occlusal and muscle balance was observed 21 days after surgery, on a condition recorded directly on the implant-supported fixed prosthesis delivered to the patient. Despite several papers in the literature addressing systems for recording the maxillomandibular relationship in implant-supported restorations for complete arches [21-27], a universally agreed-upon fully digital operating protocol, that eliminates all analog phases within a digital workflow, has not yet been established in scientific literature. Various techniques, such as custom scanning devices and fiducial markers, have been explored for intraoral scanning and maxillomandibular relationship registration [22-26]. Additionally, the use of pins positioned pre-surgery to serve as references for aligning scanning surfaces post-surgery has been noteworthy, as reported by Espona et al [27]. About the present clinical approach, a comparison with the paper published by Espona et al. should be made. [27]. The latter illustrates a digital protocol for full-arch rehabilitation with immediate loading, but more complex and with the possibility of introducing errors in the various operational steps. In fact, to create the immediate loading temporary prosthesis, the Authors make use of a superimposition between the scan of the implant scan bodies performed in the mouth on post-surgical edematous tissues and an extra-oral scan of a system (MedicalFit), which they remove from the mouth solidified with resin liquid to the temporary caps unscrewed by the MUA. Subsequently, MUA analogues are screwed in and then scanned, effectively adding an extra step. Furthermore, in the Authors' opinion, the miniscrews (Ti-System) used to record the vertical dimension of occlusion (VDO) have a different geometry from that designed for, which could be insufficient to facilitate matching due to a lack of landmarks, so much so that a tooth is left behind. Another limitation

could be that these miniscrews are also positioned in anterior areas of the jaw and it could interfere with surgery. In summary, the ScanSke approach does not include this extraoral step and the VDO information contained in the ScanSke is much more detailed than that of the small blue screws used by Espona et al [27], because the coupling is performed on many more points and surfaces as presents in the skeletal scan body. In essence, the ScanSke approach facilitates the recording of the patient's occlusion and implant positions in a fully digital workflow, during a single operational step, utilizing skeletal scan bodies. Furthermore, it leads to a temporary prosthesis made after the surgery, which will not be followed by intraoral relining of the prosthesis, as with resin before insertion into implant abutments. An additional advantage is the elimination of patient discomfort associated with receiving impressions using plaster or other materials at the end of the surgery. Nevertheless, the present paper shows a case report, and the methodology needs validation through additional research involving a larger sample size.

## CONCLUSION

According to the Authors' opinion, the clinical approach outlined in this paper describes a feasible and effective system for rehabilitating patients with terminal dentition using implant-prosthetics treatment. This method enables clinicians to utilize a digital workflow where specialized scan bodies (ScanSke) record both the patient's occlusion and the position of implants during a single clinical session.

**Institutional Review Board Statement:** The study was conducted in accordance with the Declaration of Helsinki. Ethical review and approval by an Institutional Review Board were waived for this study because the operating protocol was made during the private activity at Studio Serri Odontoiatria e Salute SRL

**Funding:** This research received no external funding.

**Conflicts of Interest:** The authors declare no conflict of interest.

## REFERENCES

- García V D, Freire Y, Fernández S D, Murillo B T, Sánchez M G. Application of the Intraoral Scanner in the Diagnosis of Dental Wear: An In Vivo Study of Tooth Wear Analysis. *Int J Environ Res Public Health* 2022;19:4481.
- Zimmermann M, Mehl A, Mörmann W H, Reich S. Intraoral scanning systems: a current overview. *Int. J Comput Dent* 2015;18:101-129.
- Joda T, Lenherr P, Dedem P, Kovaltschuk I, Bragger U, Zitzmann N U. Time efficiency, difficulty, and operator's preference comparing digital and conventional implant impressions: a randomized controlled trial. *Clin Oral Implants Res* 2017;28:1318-1323.
- Imburgia M, Logozzo S, Hauschild U, Veronesi G, Mangano C, Mangano F G. Accuracy of four intraoral scanners in oral implantology: a comparative in vitro study. *BMC Oral Health* 2017;17:92.
- Marti A M, Harris B T, Metz M J, Morton D, Scarfe W C, Metz C J, et

- al. Comparison of digital scanning and polyvinyl siloxane impression techniques by dental students: instructional efficiency and attitudes towards technology. *Eur J Dent Educ.* 2017;21:200-205.
- 6.** Lawson N C, Burgess J O. Clinicians reaping benefits of new concepts in impressioning. *Compend Contin Educ Dent.* 2015;36:152-153.
- 7.** Rheude B, Sadowsky P L, Ferreira A, Jacobson A. An evaluation of the use of digital study models in orthodontic diagnosis and treatment planning. *Angle Orthod* 2005;75:300-304.
- 8.** Azari A, Nikzad S. Flapless implant surgery: review of the literature and report of 2 cases with computer-guided surgical approach. *J Oral Maxillofac Surg* 2008;66:1015-1021. doi: 10.1016/j.joms.2007.12.010.
- 9.** van der Meer W J, Andriessen F S, Wismeijer D, Ren Y. Application of intra-oral dental scanners in the digital workflow of implantology. *PLoS One* 2012;7:e43312. doi: 10.1371/journal.pone.0043312.
- 10.** Yuzbasioglu E, Kurt H, Turunc R, Bilir H. Comparison of digital and conventional impression techniques: evaluation of patients' perception, treatment comfort, effectiveness and clinical outcomes. *BMC Oral Health* 2014;14:10. doi: 10.1186/1472-6831-14-10.
- 11.** Velasco-Ortega E, del Rocío Jiménez-Martin I, Moreno-Muñoz J, Núñez-Márquez E, Rondón-Romero J L, Cabanil-las-Balsera D, et al. Long-term treatment outcomes of implant prostheses in partially and totally edentulous patients. *Materials* 2022;15:4910.
- 12.** McClumphy E A, Hashemzadeh S, Yilmaz B, Purcell B A, Leach D, Larsen P E. Treatment of edentulous mandible with metal-resin fixed complete dentures: A 15- to 20-year retrospective study. *Clin Oral Implant Res* 2019;30:817-825.
- 13.** Gallardo Y N R, da Silva-Olivio I R, Gonzaga L, Sesma N, Martin W. A systematic review of clinical outcomes on patients rehabilitated with complete-arch fixed implant-supported prostheses according to the time of loading. *J Prosthodont* 2019;2:958-968.
- 14.** Mangano F G, Pires J T, Shibli J A, Mijiritsky E, Iezzi G, Piattelli A, et al. Early bone response to dual acid-etched and machined dental implants placed in the posterior maxilla: A histologic and histomorphometric human study. *Implant Dent* 2017;26:24-29.
- 15.** de Bruyn H, Raes S, Ostman P, Cosyn J. Immediate loading in partially and completely edentulous jaws: A review of the literature with clinical guidelines. *Periodontology* 2000 2014;66:153-187.
- 16.** Velasco-Ortega E, Cracel-Lopes J L, Matos-Garrido N, Jiménez-Guerra A, Ortiz-García I, Moreno-Muñoz J, et al. Immediate Functional Loading with Full-Arch Fixed Implant-Retained Rehabilitation in Periodontal Patients: Clinical Study. *Int J Environ Res Public Health* 2022;19:13162.
- 17.** Capparé P, Ferrini F, Ruscica C, Pantaleo G, Tetè G, Gherlone E F. Digital versus Traditional Workflow for Immediate Loading in Single-Implant Restoration: A Randomized Clinical Trial. *Biology* 2021;10:1281.
- 18.** Borgonovo A E, Rigaldo F, Battaglia D, Re D, Gianni A B. Digital Device in Postextraction Implantology: A Clinical Case Presentation. *Case Rep. Dent* 2014;2014:1-6.
- 19.** Gallardo Y R, Bohner L, Tortamano P, Pigozzo M N, Laganá D C, Sesma N. Patient outcomes and procedure working time for digital versus conventional impressions: A systematic review. *J Prosthet Dent* 2018;119:214-219.
- 20.** Rattanapanich P, Aunmeungtong W, Chaijareenont P, Khongkhunthian P. Comparative Study between an Immediate Loading Protocol Using the Digital Workflow and a Conventional Protocol for Dental Implant Treatment: A Randomized Clinical Trial. *J Clin Med* 2019;8:822.
- 21.** Ahmed W M, Verhaeghe T V, McCullagh A P G. Maxillary complete-arch implant-supported restoration: A digital scanning and maxillomandibular relationship workflow. *J Prosthet Dent* 2021;125:216-220. doi: 10.1016/j.prosdent.2020.01.010.
- 22.** Chochlidakis K, Papaspyridakos P, Tsigarida A, Romeo D, Chen Y W, Natto Z, Ercoli C. Digital versus conventional full-arch implant impressions: A prospective study on 16 edentulous maxillae. *J Prosthodont.* 2020;29:281-286. doi: 10.1111/jopr.13162.
- 23.** Chochlidakis K, Romeo D, Ercoli C, Papaspyridakos P. Complete digital workflow for prosthesis prototype fabrication with the double digital scanning (DDS) technique: A prospective study on 16 edentulous maxillae. *J Prosthodont* 2022;31: 761-765. doi: 10.1111/jopr.13569.
- 24.** Papaspyridakos P, Chen Y W, Gonzalez-Gusmao I, Att W. Complete digital workflow in prosthesis prototype fabrication for complete-arch implant rehabilitation: A technique. *J Prosthet Dent* 2019;122:189-192. doi: 10.1016/j.prosdent.2019.02.004.
- 25.** Papaspyridakos P, AlFulajj F, Bokhary A, Sallustio A, Chochlidakis K. Complete digital workflow for prosthesis prototype fabrication with double digital scanning: Accuracy of fit assessment. *J Prosthodont* 2023;32:49-53. doi: 10.1111/jopr.13492.
- 26.** Papaspyridakos P, De Souza A, Finkelman M, Sicilia E, Gotsis S, Chen Y W, Vazouras K, Chochlidakis K. Digital vs conventional full-arch implant impressions: A retrospective analysis of 36 edentulous jaws. *J Prosthodont* 2023;32:325-330. doi: 10.1111/jopr.13536.
- 27.** Espona J, Roig E, Ali A, Roig M. Immediately loaded interim complete-arch implant-supported fixed dental prostheses fabricated with a completely digital workflow: A clinical technique. *J Prosthet Dent* 2020;124:423-427. doi: 10.1016/j.prosdent.2019.08.008.
- 28.** Lekholm U, Zarb G A. Patient selection and preparation. In *Tissue Integrated Prostheses: Osseointegration in Clinical Dentistry*, 1st ed.; Branemark P I, Zarb G A, Albrektsson T Eds. Quintessence Publishing Company: Chicago, IL, USA, 1985;pp. 199-209.
- 29.** Sorrentino R, Ruggiero G, Toska E, Leone R, Zarone F. Clinical evaluation of cement-retained implant-supported cad/cam monolithic zirconia single crowns in posterior areas: Results of a 6-year prospective clinical study. *Prosthesis* 2022;4:383-393. <https://doi.org/10.3390/prosthesis4030031>.
- 30.** Moore P A, Doll B, Delie R A, Hersh E V, Korostoff J, Johnson S, et al. Hemostatic and anesthetic efficacy of 4% articaine HCl with 1: 200,000 epinephrine and 4% articaine HCl with 1: 100,000 epinephrine when administered intraorally for periodontal surgery. *J Periodontol* 2007;78:247-253.
- 31.** De Stavola L, Tunkel J. The role played by a suspended external-internal suture in reducing marginal flap tension after bone reconstruction: A clinical prospective cohort study in the maxilla. *Int J Oral Maxillofac Implants* 2014;29:921-926. doi: 10.11607/jomi.3370.
- 32.** Mokhtar A M, Hamed T, & El-Sholkamy M A. Evaluation of immediate loading mini-implant versus traditional implant (clinical and radiographic study). *Dent Sci Update* 2023;4:243-251.
- 33.** Serri, M, Papa A, Melis M. Digital bite registration of habitual occlusion with specific skeletal intraoral scan bodies for the fabrication of a fixed full-arch prosthesis on immediate loading dental implants with full digital workflow: Two case reports. *Mod Res Dent.* 2021;7:653. doi:10.31031/MRD.2021.07.000653.
- 34.** Bergkvist G. Immediate loading of implants in the edentulous maxilla. *Swed Dent J Suppl* 2008;196:10-7.
- 35.** Kim J H, Kim Y K, Yi Y J, Yun P Y, Lee H J, Kim M J, Yeo I S. Results of immediate loading for implant restoration in partially edentulous patients: a 6-month preliminary prospective study using SinusQuick™ EB implant system. *J Adv Prosthodont* 2009;1:136.
- 36.** Shayegh S, Semyari, H, Shahraki A F, kimaneh M R. Implant-retained mandibular overdentures: a comparative study of immediate loading vs delayed loading after one year. *International Journal of Oral Implantology and Clinical Research* 2012;3:105-110. <https://doi.org/10.5005/jip-journals-10012-1076>.
- 37.** Tartaglia G M, Sforza C. Functional evaluation of stomat supported prostheses. *Stomatol Edu J* 2014;1:41-47.
- 38.** Martini M, Pecora C N, Ortensi L, Pietravalle G, Paolo C D. Variation of occlusal contacts and activity of masticatory muscles. Relation to increasing the capacity of movement of the cervical spine after trust maneuver. *J Dent Health Oral Disord Ther* 2016;5:00156.